



Post-COVID-19 syndrome: morpho-functional abnormalities of the heart and arrhythmias

Chistyakova M. V., Zaitsev D. N., Govorin A. V., Medvedeva N. A., Kurokhtina A. A.

Aim. To study the myocardial morpho-functional abnormalities, the incidence and nature of cardiac arrhythmias in patients 3 months after the coronavirus disease 2019 (COVID-19).

Material and methods. The study included 77 patients (mean age, 35,9 years) treated for coronavirus infection, which underwent echocardiography and 24-hour Holter monitoring 3 months after COVID-19. The patients were divided into 3 groups: group 1 — 31 patients with upper respiratory tract involvement; group 2 — 27 patients with bilateral pneumonia (CT grade 1, 2), 3 — 19 patients with severe pneumonia (CT grade 3, 4). Statistical processing was carried out using Statistica 10.0.

Results. According to echocardiography, the peak tricuspid late diastolic velocity and isovolumetric contraction time in all groups increased ($P<0,001$). The tricuspid and mitral Em/Am ratio decreased depending on the disease severity. In group 3, the right ventricular and atrial size increased ($P<0,001$). The pulmonary artery systolic pressure, left atrial volume in patients of the 2nd and 3rd groups was higher than in the control one ($P<0,001$). In group 1 and 2 patients, the regional strain in basal and basal/middle segments decreased, respectively, while, in group 3, not only regional but also global left ventricular (LV) strain decreased ($P<0,001$). In all groups, cardiac arrhythmias and pericardial effusion were found. The relationship was established between coronavirus activity and the structural and functional myocardial parameters ($P<0,001$).

Conclusion. Cardiovascular injury 3 months after COVID-19 was found in 71%, 93%, and 95% of patients with mild,

moderate and severe course. In mild course patients, a decrease in regional myocardial strain in LV basal segments, signs of past pericarditis, and various cardiac arrhythmias were noted. In patients of moderate severity, these changes were more pronounced and were accompanied by an additional decrease in regional strain in LV middle segments, impaired right ventricular diastole and increased pulmonary artery pressure. In severe patients, in addition to the above changes, dilatation of the right heart and inferior vena cava was recorded, as well as LV diastolic and global systolic function decreased.

Keywords: heart, COVID-19, arrhythmia.

Relationships and Activities: none.

Chita State Medical Academy, Chita, Russia.

Chistyakova M. V.* ORCID: 0000-0001-6280-0757, Zaitsev D. N. ORCID: 0000-0002-2741-3783, Govorin A. V. ORCID: 0000-0003-1340-9190, Medvedeva N. A. ORCID: 0000-0002-3602-4034, Kurokhtina A. A. ORCID: 0000-0002-7086-773X.

*Corresponding author:

marina_vladi@internet.ru

Received: 25.04.2021

Revision Received: 08.06.2021

Accepted: 03.07.2021



For citation: Chistyakova M. V., Zaitsev D. N., Govorin A. V., Medvedeva N. A., Kurokhtina A. A. Post-COVID-19 syndrome: morpho-functional abnormalities of the heart and arrhythmias. *Russian Journal of Cardiology*. 2021;26(7):4485. (In Russ.) doi:10.15829/1560-4071-2021-4485

A dangerous infectious disease, coronavirus disease 2019 (COVID-19), is still characterized by high morbidity and mortality. It is known that mild to moderate course is most common, but majority of COVID-19 survivors note a slow recovery rate. A year after the pandemic start, it was established that the virus is dangerous with long-term complications (post-COVID-19 syndrome). Thus, numerous studies confirm long-term involvement of some organs and systems, including the lungs, brain, kidneys, as well as the cardiovascular system with developing severe heart injury [1-13]. There is evidence that there is a direct effect of virus on cardiomyocytes with destruction, as well as vascular endothelial damage with impaired microcirculation and formation of multiple thrombosis [1-2]. In some patients, as a result of immune response, a cytokine storm develops causing fulminant myocarditis, heart failure, and cardiogenic shock [2, 4, 11]. Myocardial damage can also result from aggressive treatment methods for COVID-19 [7].

When studying the cardiovascular system of professional athletes in the United States, the detection rate of myocarditis after COVID-19 (mild or asymptomatic) ranged from 15% to 30% [13]. At autopsy of 39 patients after COVID-19, SARS-CoV-2 virus were found in the heart in more than 60%, while 16 people had clinically significant levels of tissue viral load at the time of death [14]. In addition, a cardiovascular involvement was revealed in patients on average 71 days after COVID-19 diagnosis [15]. According to magnetic resonance imaging, in 78% of subjects, an increase in the volume and mass of myocardium and a decrease in left ventricular (LV) ejection fraction (LVEF) were found; myocardial biopsy revealed active lymphocytic inflammation in 60% of patients [15].

In this regard, the aim of our study was to investigate myocardial morpho-functional abnormalities, the incidence and nature of cardiac arrhythmias in patients 3 months after COVID-19.

Material and methods

Seventy-seven patients treated for COVID-19 3 months (median, 98 days) after the diagnosis, the heart was examined: echocardiography using Vivid E95 ultrasound system, Holter electrocardiography (ECG) monitoring (HM). The virus was identified with polymerase chain reaction test for SARS-CoV-2. All COVID-19 survivors before the disease were practically healthy and did not note chronic diseases, including cardiovascular ones. The patients were divided into 3 groups: 1 (n=31) — patients without complications (with upper respiratory tract involvement), who were treated on an outpatient basis (according to computed tomography (CT),

lungs were not involved); 2 (n=27) — patients with bilateral, multisegmental, viral/bacterial pneumonia, CT 1, <25% (n=16) and CT 2, 25-50% (n=11); 3 (n=19) — patients with severe course, CT 3-4 (n=11), CT 4 (n=8). The mean age of patients in group 1 was 35,5 [23; 46] years, 2 — 36 [27; 43,5] years, 3 — 36,9 [35,2; 48] years. According to CT, all patients of group 2 had bilateral lung involvement, moderate fibrous and interstitial changes, pleuropulmonary adhesions, and irregular-shaped ground-glass opacities. In patients of group 3 with moderate fibrous and interstitial changes, dense areas of parenchymal infiltration are observed due to interstitial interlobular and consolidation. Patients in both groups had single moderately enlarged mediastinal lymph nodes. Group 1 patients took antiviral drugs, vitamin C, diazolin. Patients of groups 2 and 3 received antibiotics of the macrolide group, third-generation cephalosporins, anti-coagulants, expectorant and antiviral drugs. Patients of group 3 were also prescribed detoxification agents. In addition, 17 (58%) patients in group 2 and all patients in group 3 were prescribed conventional hydroxychloroquine therapy. It should be noted that according to current guidelines of the Russian Ministry of Health for prevention, diagnosis and treatment of COVID-19 (version 11, revision of 07.05.2021), hydroxychloroquine is excluded from the list of recommended therapy at all disease stages, while this study was conducted at the time of earlier guidelines version, which included chloroquine drugs in combination therapy for COVID-19.

The control group consisted of 22 healthy volunteers of comparable age without COVID-19, who had negative test for anti-SARS-CoV-2 IgM and IgG antibodies.

Doppler echocardiography was performed according to standard technique using VIVID E95 ultrasound system. Doppler echocardiography was performed using apical 2- and 4- chamber view. Spectral Doppler signal was recorded from annulus of mitral, tricuspid valves and ventricular segments. The following parameters were estimated: peak myocardial systolic (Sm), early diastolic (Em), and late diastolic (Am) velocities, Em/Am ratio, myocardial isovolumetric contraction (IVC) period, isovolumetric relaxation (IVR) period.

Regional longitudinal strain and LV strain rate were investigated using two-dimensional non-Doppler strain imaging. The investigation was performed using the apical long axis view with a frame rate of 50 to 80 frames per sec with ECG monitoring. Endocardium was manually traced, while epicardial surface was traced automatically. The program estimated from frame to frame the displacement of spots area-of-interest throughout

Table 1

Doppler echocardiography and Holter ECG monitoring data in patients after COVID-19

Parameters	Control, n=22	Group 1, n=31	Group 2, n=27	Group 3, n=19
Tricuspid A, cm/s	0,29 [0,27;0,31]	0,33 [0,32;0,41]*	0,41 [0,38;0,48]*,†	0,49 [0,3;0,6]*,†,§
Tricuspid annular Am, cm/s	0,13 [0,11;0,14]	0,15 [0,11;0,18]*	0,16 [0,12;0,18]*,†	0,41 [0,38;0,88]*,†,§
Tricuspid annular Em/Am	1,21 [1,09;1,31]	0,91 [0,90;1,36]*	0,8 [0,65;1,06]*,†	0,73 [0,38;0,92]*,†,§
IVC, ms (RV)	67,3 [62,5;72,4]	81,5 [73;82]	82 [72,7;98,5]	92 [71;99,1]*
Inferior vena cava diameter, mm	17,3 [15,2;20,1]	20,5 [12,4;21,3]	21,9 [15,3;22,4]	26,3 [24,8;27,4]*
RV, mm	27 [22,1;32,3]	29,4 [22,9;33,1]	32,8 [25,3;35,8]	34,2 [28,1;35,1]*,†,§
RAVI, ml/m ²	21,3 [18,4;22,8]	21,8 [20,7;24,5]	22,5 [18,9;23,3]	25 [24,1;25,4]*,†,§
LA pressure, mm Hg	27,3 [22,1;32,3]	29,4 [22,9;33,1]	35,8 [25,9;36,8]*	39,7 [28,1;45,2]*,§
Mitral annular Em/Am	1,3 [1,2;1,77]	1,36 [1,04;1,7]	1,1 [0,8;1,36]*	0,9 [0,3;1,42]*,†,§
Mitral annular Em, cm/s	13,3 [9,1;15,4]	12 [10,1;15,18]*	10 [8,12;13,18]*	9,3 [6,42;12,1]*,†,§
LAVI, ml/m ²	20,3 [18,5;23,4]	22,5 [20,75;23,5]	22,8 [20,4;24,1]*	24,2 [24,8;26,4]*,§
E/Em	6,13 [5,11;7,14]	6,15 [5,11;7,18]	7,16 [7,12;9,18]*	8,1 [8,42;12,88]*,§
SDNN	136 [122;177]	121 [107;173]*	104 [97;197]*	117 [96;210]*
Lf/Hf	2,57 [2,49;3,6]	3,39 [2,5;4,9]*	5,5 [2,9;6,8]*	4,9 [2,5;6,1]*

Note: * — significance of differences compared with control group ($P<0,001$), † — significance of differences compared with group 1 ($P<0,001$), § — significance of differences compared with group 2 ($P<0,001$).

Abbreviations: Tricuspid A, cm/s — peak late diastolic tricuspid velocity; Tricuspid annular Am, cm/s — late diastolic tricuspid annular velocity; Tricuspid annular Em/Am — diastolic tricuspid annular velocity ratio; IVC, ms (RV) — tricuspid annular isovolumetric contraction period; RV, mm — right ventricle diastolic dimension; RAVI, ml/m² — right atrial volume index; Mitral annular Em/Am — diastolic mitral annular velocity ratio; LAVI, ml/m² — left atrial volume index; E/Em — left ventricular filling pressure; SDNN — standard deviation of all normal sinus R-R intervals; Lf/Hf — ratio of power in the high frequency band of HRV spectrum (0,15-0,40 Hz) to power in the low frequency band of HRV spectrum (0,04-0,15 Hz).

the entire cardiac cycle. After optimization of area-of-interest, the software generated strain curves for each segment.

Holter ECG monitoring was performed using the Astrocord system. The analysis of heart rate variability (HRV) was carried out in accordance with guidelines of the European Society of Cardiology and the North American Society of Pacing and Electrophysiology. HRV was studied by statistical analysis obtained with 24-hour ECG monitoring, with the estimation of following parameters: 1) temporal: average heart rate in 1 min, standard deviation of all normal sinus R-R intervals (SDNN), standard deviation of the 5-minute mean R-R intervals (SDANN), SDNN index, root mean square of consecutive R-R intervals (RMSSD), and percentage of successive R-R intervals differing by more than 50 ms (pNN50); 2) spectral, obtained using the fast Fourier transform: power in the high frequency band of HRV spectrum (0,15-0,40 Hz) — HF, power in the low frequency band of HRV spectrum (0,04-0,15 Hz) — LF, LF/HF ratio. The study was carried out in accordance with Good Clinical Practice and Declaration of Helsinki. The study protocol was approved by the ethics committees of all participating clinical centers. Written informed consent was obtained

from all participants. There were no potential study limitations. Statistical processing was carried out using the statistical software package Statistica 10.0. Distribution of almost all variation series was non-normal; therefore, the analysis used nonparametric statistics methods. Differences between groups were assessed using the nonparametric Mann-Whitney test. Correlation analysis was performed using Spearman's rank correlation coefficient.

Results

Ninety eight [92; 103] days after the diagnosis of COVID-19, almost all patients with mild (n=26; 83,8%), moderate (n=24; 89%) and severe course (n=18; 94,7%) had complaints for asthenia, fatigue, performance impairment, sleep loss. Chest pain was noted by 4 (13%) patients of group 1, 9 (33,3%) patients of group 2 and 11 (57%) of group 3, while mixed dyspnea was found in 7 (22,5%), 14 (51,8%) and 12 (63%) patients, respectively. Palpitations was revealed in 3 (9,6%) patients with mild COVID-19, 10 (37%) patients with moderate and 15 (78%) patients with severe disease. Hypertension was detected in 4 (12,9%), 4 (14,8%) and 9 (47%) patients of group 1, 2 and 3, respectively.

According to echocardiography, the peak late diastolic tricuspid velocity (A), as well as late

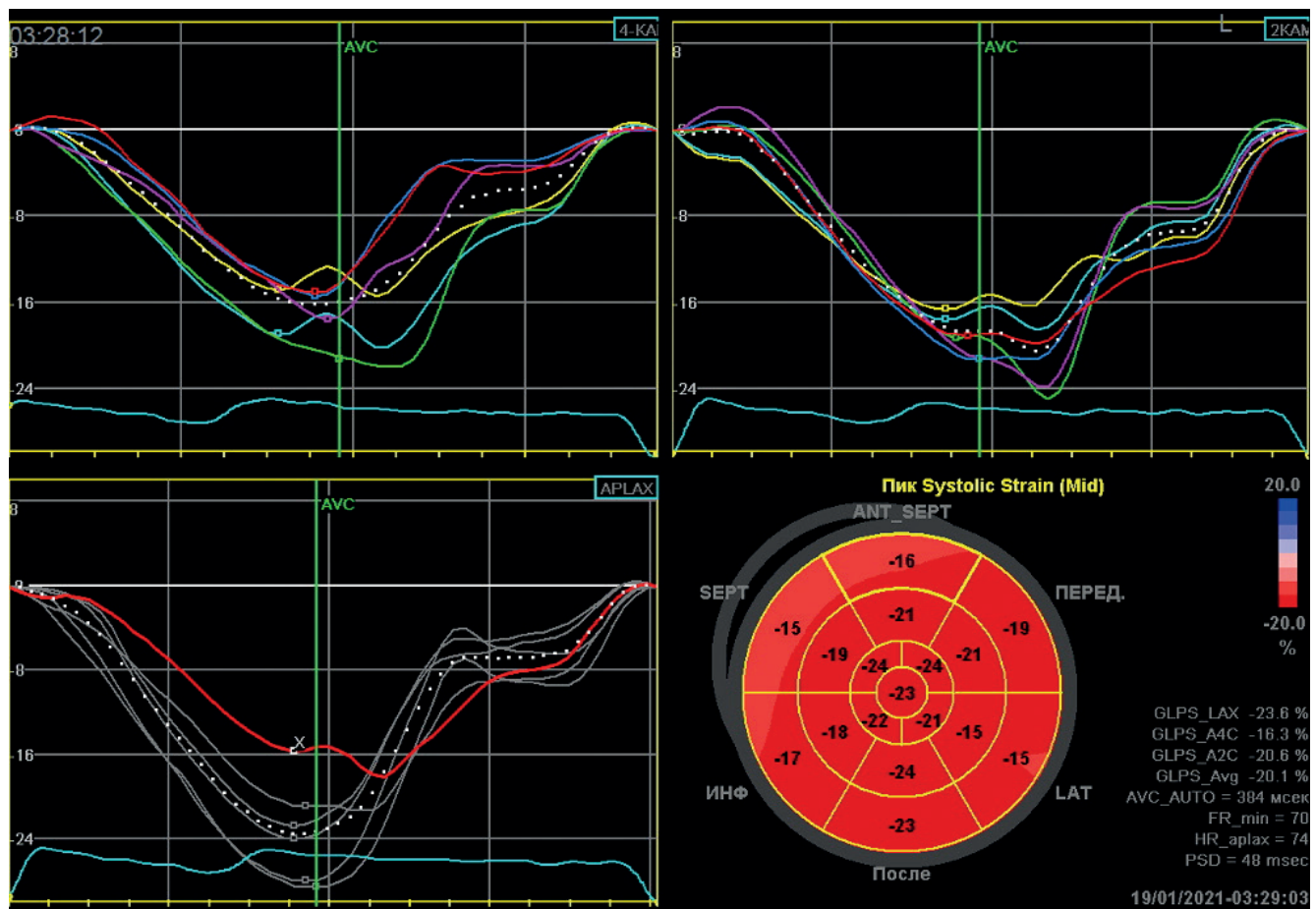


Figure 1. Regional diastolic strain in Bull's Eye mode in a patient of group 1 after COVID-19. A decrease in regional systolic function in the LV basal septal, basal antero-septal and anterior segments is revealed.

diastolic tricuspid annular velocity (Am) increased in all groups, while the Em/Am ratio, on the contrary, decreased depending on disease severity (Table 1) ($P < 0,001$). Right ventricular (RV) IVC period and inferior vena cava diameter were higher in patients in group 3, in contrast to the control group. There was an increase in right heart sizes in patients with a severe COVID-19. The systolic pulmonary artery pressure in patients of groups 2 and 3 was higher than in the control group, while the highest value was in patients with a severe disease course and amounted to 39,7 [28,1; 45,2] mm Hg. The established changes suggest an impaired RV diastolic function in patients after COVID-19, and these violations worsened with an increase in disease severity. Patients with severe COVID-19 also showed an increase in right heart sizes, inferior vena cava and pulmonary artery pressure.

When studying LV diastolic function by tissue Doppler echocardiography in patients of groups 2 and 3, a decrease in Em/Am ratio and Em in comparison with the control group was revealed, while more pronounced abnormalities were found

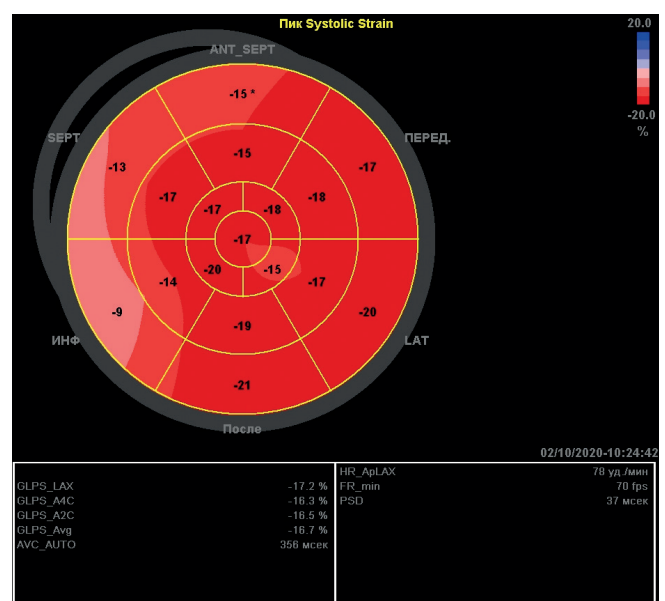


Figure 2. Regional diastolic strain in Bull's Eye mode in a patient of group 3 after COVID-19. A decrease in regional systolic function in the LV basal and middle septal, basal antero-septal and basal anterior segments is revealed.

Table 2

Parameters of LV longitudinal strain in patients after COVID-19 (in %)

Segments	Control group	Group 1	Group 2	Group 3
Septal segments				
Basal	-21 [19;24,5]	-17 [16;20]*	-16,5 [14;19,7]*,†	-15,9 [14,5;18,8]*,†
Middle	-21 [19;22]	-21 [15;23]	-14,5 [12,7;17,2]*	-16 [14,7;18,5]*
Antero-septal segments				
Basal	-21 [19,5;23]	-17 [16;19]*	-16,5 [16;19,7]*,†	-16,3 [15,1;21,7]*,†
Middle	-21 [19;22]	-18 [21;21,05]	-14,5 [11,7;18]*	-15,4 [14,1;20,1]*
Anterior segments				
Basal	-22 [19,3;24,6]	-22 [17;23]	-18,5 [14,7;20,2]*	-16,8 [15,3;20]*
Middle	-22 [19,1;25,5]	-24 [18;25,3]	-17,5 [17,2;19,7]*	-17,2 [15,3;19,1]*
Apical	-23 [19,5;24,5]	-21 [20;23]	-17,5 [17,2;19]*	-17,8 [13,5;19,5]*
Lateral segments				
Middle	-21 [19;24]	-17 [20;21]	-13 [10,5;14,7]*	-13 [12;17]*
Apical	-22 [19,4;23]	-18,3 [17,3;22,4]	-16 [15,5;19,7]*	-13,8 [12,3;17,9]*
Posterior segments				
Basal	-18 [17;21]	-17,2 [16;20]*	-15,4 [15;20,7]*,†	-15 [14,5;21]*,†
Middle	-20 [18,5;21]	-18 [16;19]	-16 [13,2;18,7]*	-15,4 [13,8;19,2]*
Inferior segments				
Basal	-20 [18,4;21]	-18 [16;22,5]	-16 [13,3;18,9]*	-17 [14;19]*
Middle	-21 [19;24]	-21,4 [17;21,8]	-18,3 [10,5;18,9]	-17 [12,5;22]*,†
Avg	-21 [19,6;22,5]	-20,8 [18,1;21,9]	-21 [20,8;22,1]	-17,75 [14,6;19,4]*,†

Note: * — significance of differences compared with control group ($P < 0,001$), † — significance of differences compared with group 1 ($P < 0,001$).

Abbreviation: Avg — global systolic strain.

in patients with severe COVID-19. In addition, in patients with moderate and severe course, left atrial volume increased, as well as the LV end-diastolic pressure (E/Em); these disorders were more pronounced in patients with a severe disease course (Table 1) ($P < 0,001$). Thus, in patients with a moderate and severe COVID-19, a LV diastolic dysfunction develops, and more pronounced abnormalities regard patients after severe COVID-19.

In 4 (19,9%), 7 (22%), and 5 (26,3%) patients of group 1, 2, and 3, respectively, pericardium was involved in the inflammatory process: according to echocardiography, an insignificant amount of fluid in pericardial cavity was revealed. In addition, in 3 (11%) patients with moderate and 3 (15,7%) patients with severe course, there was a pericardial thickening, mainly behind the LV posterior wall.

Studying the LV longitudinal strain using the Speckle Tracking technology, there was a decrease in regional strain rate in the LV basal segments (septal, antero-septal and posterior) in patients of experimental groups compared with control one. Moreover, in patients with a moderate and severe

disease course, this parameter was lower than in patients with a mild COVID-19 ($P < 0,001$). In comparison with control group, patients of groups 2 and 3 also showed a decrease in regional strain rate in LV basal segment of inferior wall, middle segments (septal, antero-septal, anterior, lateral, and posterior). In addition, in groups 2 and 3, the regional strain rate in LV apical segments of anterior and lateral walls decreased. In patients with severe course, there was a decrease in regional velocity in the middle segment of inferior wall, a decrease in LV global systolic function in comparison with control and first groups (Figure 1, 2, Table 2). Revealed areas with reduced regional strain rate correspond to blood supply system of left anterior descending artery and right coronary artery and, possibly, indicate an impaired regional LV function, which is a marker of myocardial ischemia. In patients with severe course, not only the regional strain rate decreased, but also the global LV systolic function.

According to 24-hour ECG monitoring, in patients of groups 2 and 3, cardiac arrhythmias were most often represented by supraventricular premature beats (in 15 (55%) and 13 (68,4%)

patients, respectively), ventricular premature beats (in 8 (29,6%) and 11 (57,8%) patients, respectively), atrial fibrillation (in 1 (3,7%) and 2 (10%) patients, respectively), nonsustained supraventricular tachycardia (2 (7%) and 6 (31,5%), respectively), QT interval prolongation (in 2 (7%) and 6 (31,5%), respectively). In addition, in these groups there was a decrease in total HRV SDNN, an increase in Lf/Hf ratio, which probably indicates a shift in autonomic balance towards sympathetic nervous system (Table 1). Patients of group 1 were found to have supraventricular (n=6 (19,3%)) and ventricular (n=3 (9,6%)) premature beats, nonsustained supraventricular tachycardia (n=3 (9,6%)).

Analysis of correlation between coronavirus (+) RNA activity and myocardial structure and function revealed that (+) RNA correlated with Em/Am ratio ($r=0,75$, $P<0,001$), pulmonary artery pressure ($r=0,60$, $P<0,001$) and global LV systolic strain ($r=0,54$, $P<0,001$). Given these data, it can be assumed that coronavirus activity contributes to disruption of cardiac structure and function with an increase in pulmonary artery pressure.

Discussion

Thus, 3 months after the diagnosis of COVID-19, cardiovascular disorders were detected in 22 (71%), 25 (93%), and 18 (95%) patients with mild, moderate, and severe disease course, respectively. It is possible that after the penetration of virus into upper respiratory tract in patients with a mild disease course, an early immune system response to the pathogen occurs. A pronounced immune response restrains the infection, but heart is still involved, which is manifested by a decrease in Em/Am and an increase in peak late diastolic tricuspid velocity. In addition, in this group, there is a decrease in myocardial regional strain rates of the basal segments of septal, antero-septal areas, the posterior wall of LV, as well as arrhythmias and signs of pericarditis were revealed. In patients with moderate severity, in addition to above abnormalities, more segments with a decrease in regional strain rate were revealed; in addition to the basal segments, strain rate in the middle LV segments decrease, RV diastole is impaired, and pulmonary artery pressure rises. More pronounced structural and functional cardiac abnormalities were found in patients with severe course: there were more segments with decreased in regional strain rate; in addition to the basal, the middle and apical segments of LV decreased; LV global longitudinal strain was also reduced. Diastolic

dysfunction of not only the RV, but also the LV were revealed. In addition, right heart was enlarged, as well as inferior vena cava diameter and pulmonary artery pressure increased.

Thus, more severe the disease progresses, the more LV segments are involved, and most often — the segments of interventricular septum. It should be noted that in-depth assessment of cardiac function may be a strong predictor of stable myocardial ischemia. Possibly, these disorders occur as a result of endothelial dysfunction and injury of small coronary vessels [1-4, 10], activation of inflammation factors by cytokines and immune complexes, as well as due to effect of viruses on cardiomyocytes with fibrosis formation [5, 11], which can be manifested by increased stiffness and impaired LV diastolic function.

The studied correlations established between the viral (+) RNA and diastolic tricuspid annular velocities, pulmonary artery pressure and global LV systolic strain, can confirm the direct toxic effect of viruses on myocardium with an impairment of its structure and function.

In addition, a decrease in vagal control, impaired myocardial metabolism, its increased rigidity contributes to arrhythmias, in the development of which toxic drugs such as hydroxychloroquine, antiviral agents, and some antibiotics causing QT interval prolongation can play an important role [1, 5, 6].

Conclusion

Cardiovascular injury 3 months after COVID-19 was found in 71%, 93%, and 95% of patients with mild, moderate and severe course. In mild course patients, a decrease in regional myocardial strain in LV basal segments, signs of past pericarditis, and various cardiac arrhythmias were noted. In patients of moderate severity, these changes were more pronounced and were accompanied by an additional decrease in regional strain in LV middle segments, impaired right ventricular diastole and increased pulmonary artery pressure. In severe patients, in addition to the above changes, dilatation of the right heart and inferior vena cava was recorded, as well as LV diastolic and global systolic function decreased. Given these data, for timely diagnosis of long COVID, all patients after disease are recommended to conduct an echocardiography and 24-hour ECG monitoring.

Relationships and Activities: none.

References

1. Wei ZY, Qian HY. Myocardial injury in patients with COVID-19 pneumonia. *Zhonghua XinXue GuanBing ZaZhi*. 2020;48(0):E006. doi:10.3760/cma.j.issn.cn112148-20200220-00106.
2. He XW, Lai JS, Cheng J, et al. Impact of complicated myocardial injury on the clinical outcome of severe or critically ill COVID-19 patients. *Zhonghua XinXue GuanBing ZaZhi*. 2020;48(6):456-60. doi:10.3760/cma.j.cn112148-20200228-00137.
3. Shlyakho EV, Konradi AO, Arutyunov GP, et al. Guidelines for the diagnosis and treatment of circulatory diseases in the context of the COVID-19 pandemic. *Russian Journal of Cardiology*. 2020;25(3):3801. (In Russ.) doi:10.15829/1560-4071-2020-3-3801.
4. Bubnova MG, Shlyakho EV, Aronov DM, et al. Coronavirus disease 2019: features of comprehensive cardiac and pulmonary rehabilitation. *Russian Journal of Cardiology*. 2021;26(5):4487. (In Russ.) doi:10.15829/1560-4071-2021-4487.
5. Poteshkina NG, Lysenko MA, Kovalevskaya EA, et al. Cardiac damage in patients with COVID-19 coronavirus infection. "Arterial'naya Gipertenziya" ("Arterial Hypertension"). 2020;26(3):277-87. (In Russ.) doi:10.18705/1607-419X-2020-26-3-277-287.
6. Huang C, Wang Y, Li X, et al. Clinical features of patients infected with 2019 novel coronavirus in Wuhan, China. *Lancet*. 2020;395(10223):497-506. doi:10.1016/S01406736(20)30183-5.
7. Arutyunov GP, Tarlovskaya EI, Arutyunov AG, et al. International register "Dynamics analysis of comorbidities in SARS-CoV-2 survivors" (AKTIV SARS-CoV-2): analysis of predictors of short-term adverse outcomes in COVID-19. *Russian Journal of Cardiology*. 2021;26(4):4470. (In Russ.) doi:10.15829/1560-4071-2021-4470.
8. Post-covid syndrome in individuals admitted to hospital with covid-19: retrospective cohort study. *BMJ*. 2021;372:n693. doi:10.1136/bmj.n693. (Published 31 March 2021).
9. Guo T, Fan Y, Chen M, et al. Cardiovascular Implications of Fatal Outcomes of Patients With Coronavirus Disease 2019 (COVID-19). *JAMA Cardiol*. 2020;5(7):811-8. doi:10.1001/jamacardio.2020.1017.
10. Kogan EA, Berezovskiy YuS, Blagova OV, et al. Myocarditis in Patients with COVID-19 Confirmed by Immunohistochemical. *Kardiologia*. 2020;60(7):4-10. (In Russ.) doi:10.18087/cardio.2020.7.n1209.
11. Krishnamoorthy P, Croft LB, Ro R, et al. Biventricular strain by speckle tracking echocardiography in COVID-19: findings and possible prognostic implications. *Future Cardiology*. 2020;17(4). doi:10.2217/fca-2020-0100.
12. Szekeley Y, Lichter Y, Taieb P, et al. Spectrum of Cardiac Manifestations in COVID-19: A Systematic Echocardiographic Study. *Circulation*. 2020;142(4):342-53. doi:10.1161/CIRCULATIONAHA.120.047971.
13. Fend C. The real cause of post-COVID myocarditis is anxiety: MedPage <https://www.medpagetoday.com/> (8 September 2020).
14. Lindner D, Fitzek A, Bräuninger H, et al. Association of Cardiac Infection With SARS-CoV-2 in Confirmed COVID-19 Autopsy Cases. *JAMA Cardiol*. 2020:e203551. doi:10.1001/jamacardio.2020.3551.
15. Puntmann VO, Carerj ML, Wieters I, et al. Outcomes of Cardiovascular Magnetic Resonance Imaging in Patients Recently Recovered From Coronavirus Disease 2019 (COVID-19). *JAMA Cardiol*. 2020:e203557. doi:10.1001/jamacardio.2020.3557.